

FOLIA MEDICA CRACOVIENSIA

Vol. LIX, 1, 2019: 37–47

PL ISSN 0015-5616

DOI: 10.24425/fmc.2019.128024

Parechovirus and enterovirus infections in neonates

MAŁGORZATA KIELAR¹, ALEKSANDRA TOKARZ¹, PAULINA DUMNICKA²,
MAŁGORZATA MARAJ³, BOŻENA BURZYŃSKA⁴, STANISŁAW STĘPNIEWSKI⁴

¹Medical Diagnostic Laboratory with a Bacteriology Laboratory, St. Louis Regional Children's Hospital
Kraków, Poland

²Department of Medical Diagnostics, Faculty of Pharmacy, Jagiellonian University Medical College
Kraków, Poland

³Department of Physiology, Jagiellonian University Medical College, Kraków, Poland

⁴Department of Neonatology, St. Louis Regional Children's Hospital, Kraków, Poland

Corresponding author: Małgorzata Kielar, MSc

Medical Diagnostic Laboratory with Bacteriology Laboratory, St. Louis Regional Children's Hospital

ul. Strzelecka 2, 31-503 Kraków, Poland

Phone: +48 12 619 86 47; E-mail: gkielar@tlen.pl

Abstract: Background: Parechovirus and enterovirus belong to a family of Picornaviridae, non-enveloped, small-sized RNA viruses, responsible for multiple human diseases. Recent introduction of molecular tests enabled the identification of parechovirus and enterovirus infections. Our aim was a retrospective analysis of signs and symptoms associated with confirmed parechovirus or enterovirus infections among children treated in the Department of Neonatology, St. Louis Regional Children's Hospital in Kraków, Poland.

Methods: Based on laboratory records, we identified all cases of parecho- or enterovirus infections confirmed by identification of viral RNA in nasal swab or cerebrospinal fluid samples. Hospital records and laboratory tests results of selected patients were then analyzed, and selected data were summarized, with emphasis on clinical and laboratory findings at admission.

Results: We identified 11 cases of parechovirus and three of enterovirus infections. All cases were neonates admitted to hospital with fever and irritability. Except for leukopenia in 50% of patients, no significant abnormalities were noted in blood counts and serum biochemistry, including low C-reactive protein and procalcitonin. In nine cases, cerebrospinal fluid was collected, the fluid protein concentrations and cell counts were moderately increased. Final diagnosis was meningitis in 12 children, and other viral infections in two.

Conclusions: Viral infection, including parecho- and enteroviruses, should be considered in the etiology of fever and meningitis in neonates. The available molecular tests allow for detection of viral genetic material even in a scant biological specimen collected from neonates.

Key words: human parechovirus, human enterovirus, infection, infants, neonates.

Introduction

The development of modern laboratory techniques, especially in molecular biology, has allowed for diagnosis of former unrecognized infections. Identification of viral diseases for many years had been based on time-consuming viral culture, primarily on cell lines. Currently, the advancement in the diagnostics of viral infections and the development of new techniques based on polymerase chain reaction (PCR) allow for the detection of genetic material of various microorganisms in a relatively short time.

Parechovirus and enterovirus genera belong to a widely spread family of Picornaviridae (Greek *Pico* — very small) characterized by small size of 20–35 nm, positive sense single-stranded RNA, and lack of envelope — the feature influencing their relatively high resistance to environmental factors and the ways of transmission. The viruses belonging to Picornaviridae family (including also hepatovirus, cardiovirus and aphthovirus genera) are responsible for multiple human diseases, although in many cases, the infections in humans are asymptomatic.

Enterovirus genus includes several species pathogenic to humans (enterovirus A–D and rhinovirus A–C). The viruses may cause widespread infections of digestive tract, respiratory infections, or conjunctivitis, but may lead to myocarditis, meningitis and severe multi-organ disease. Within parechovirus genus, in turn, four species (A–D) have been identified. Gene sequencing enabled distinguishing of 19 genotypes of parechovirus A called human [1–3]. Viruses belonging to the Picornaviridae family are the most serious threat to neonates and infants [1, 4], mainly because of the immature immunological system of the youngest children.

The symptoms of viral infections remain ambiguous and non-specific as they include fever, irritability, anxiety, often a rash, diarrhea and cough [1–4]. Both parechoviruses and enteroviruses can cause meningitis and sepsis in neonates [1, 2]. The viruses can spread via multiple pathways including fecal-oral, air and vertical transmission [5]. In the course of the infections, viremia may result in secondary site tissue infections. The material collected for laboratory examinations is very diverse and includes not only stool and samples from respiratory tract, but also blood and cerebrospinal fluid [1].

In our center, molecular tests that enable identification of parechovirus and enterovirus RNA, have been introduced in the year 2017. The aim of the study was to

analyze the clinical signs and symptoms as well as laboratory test results accompanying the confirmed parechovirus and enterovirus infections in children hospitalized at the Department of Neonatology, St. Louis Regional Children's Hospital in Kraków, Poland.

Materials and Methods

This was a retrospective analysis of patients' data from single center, the St. Louis Regional Children's Hospital in Kraków, Poland. This is a 111-bed specialist pediatric center, including neonatology ward. Based on the hospital laboratory records, we identified all cases of laboratory confirmed parechovirus or enterovirus infection admitted to the Department of Neonatology of the hospital. For the identified cases, retrospective data analysis was carried out based on the patients' hospital records and laboratory test results (microbiological, hematological, biochemical and immunochemical). A necessary permission allowing for the utilization of patients' records and test results was obtained.

The analysis included demographic data (age, sex), date of admission, signs and symptoms recorded at the admission, time of hospital stay and final diagnosis, laboratory test results recorded on admission (peripheral blood smear, biochemical tests including the serum activity of transaminases: aspartate (AST) and alanine (ALT), serum concentrations of urea, creatinine, C-reactive protein (CRP), procalcitonin (PCT), glucose, and electrolytes i.e. total calcium, magnesium, sodium, potassium, and chloride) and microbiological tests: blood, urine and stool cultures as well as molecular identification of pneumotropic and neurotropic viruses. In a part of patients, biochemistry and cell count of cerebrospinal fluid were also performed.

Nasal swab samples were collected for identification of pneumotropic viruses, and cerebrospinal fluid was collected by lumbar puncture for identification of neurotropic viruses. The viral RNA was detected by real time PCR with the use of FTlyo Respiratory pathogens 21 (for nasal swab samples) and FTD Neuro9 (for cerebrospinal fluid samples) (both kits from Fast Track Diagnostics Ltd., Sliema, Malta). The FTlyo Respiratory test detects influenza A virus, influenza B virus, influenza A(H1N1) virus, human rhinovirus, human coronavirus NL63, human coronavirus 229E, human coronavirus OC43, human coronavirus HKU1, human parainfluenza 1, human parainfluenza 2, human parainfluenza 3, human parainfluenza 4, human metapneumoviruses A/B, human bocavirus, human respiratory syncytial viruses A/B, human adenovirus, enterovirus, and human parechovirus; additionally to the mentioned viruses, the test detects *Mycoplasma pneumoniae*. The FTD Neuro9 test detects human adenovirus, human cytomegalovirus, Epstein-Barr virus, enterovirus, human parechovirus, herpes simplex virus 1, herpes simplex virus 2, varicella zoster virus, human herpesvirus 6, human herpesvirus 7, and human parvovirus B19. The tests were carried out in Department of Microbiology, University Hospital, Kraków,

Poland. Biochemistry and cell count of cerebrospinal fluid were performed at the Department of Diagnostics, University Hospital, Kraków, Poland.

The remaining laboratory tests were conducted at the Medical Diagnostic Laboratory with a Bacteriological Laboratory of the St. Louis Regional Children's Hospital in Kraków. The biochemical tests were performed using automatized analyzer Vitros FS 5.1. (Ortho Clinical Diagnostics, Raritan, NJ, USA), and the complete blood counts using hematological analyzer Sysmex XN 550 (Sysmex Corporation, Kobe, Japan). The microbiological cultures were performed using manual methods. Blood cultures were carried out on Bact Alert (BioMerieux, Marcy-l'Étoile, France) for 5 days in aerobic conditions, whereas other cultures on Oxoid plates (Thermo Fisher Scientific, Waltham, MA, USA). Bacteria were identified by means of biochemical tests purchased from Erba Lachema s.r.o. (Brno, Czech Republic) and antimicrobial susceptibility of cultured microorganisms was tested with disc-diffusion method.

Distribution of quantitative variables was assessed with Shapiro-Wilk test. For normally distributed variables, we reported the mean, standard deviation and range, while in case of non-normal distribution, median, lower, upper quartile and range. For qualitative data, we reported the number of children in a given category and the percentage of the group. Statistica 12 (StatSoft, Tulsa, OK, USA) was used for computation.

Results

In 2018, the Department of Neonatology of St. Louis Regional Children's Hospital in Kraków, Poland requested the tests towards neurotropic or pneumotropic viruses in 19 nasal swab samples and nine cerebrospinal fluid samples of 28 patients aged 4 days to six weeks. Among the patients, parechovirus or enterovirus RNA was detected in the nasal swab or cerebrospinal fluid samples of 14 children.

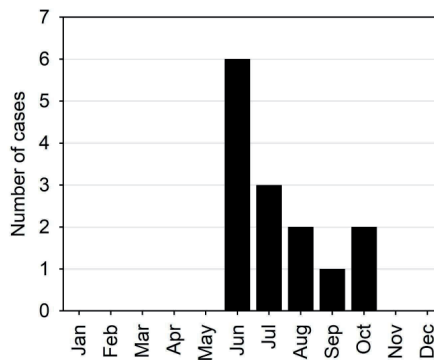


Fig. 1. Number of cases with confirmed parechovirus and enterovirus infection recorded in subsequent months of the year 2018.

All confirmed cases concerned neonates aged 4 to 28 days, hospitalized at the Neonatology Department in the period between 7th June and 12th October 2018 (Fig. 1). The children were born at 37 till 41 weeks of pregnancy, eight children (57%) were born by Cesarean section. Except for one neonate, all were born with Apgar score of 9 or 10. The one had Apgar score of 6 at first due to birth asphyxia, but it rose to 8 and 10 points in the following examinations and no further complications were reported. One child had history of dyspnea and increased C-reactive protein and was treated with antibiotics (ampicillin, cefuroxime, azithromycin) during two weeks after birth. Except for one, the neonates were breast-fed. Demographic and clinical data of the patients were presented in Table 1.

Table 1. Characteristics of studied patients with confirmed parechovirus or enterovirus infections.

Characteristic	Values
Sex:	
Female, n (%)	5 (35.7)
Male, n (%)	9 (64.3)
Age <1 month, n (%)	14 (100)
Age, days	
Median (Q1; Q3); minimum-maximum	21 (14; 21); 4–28
Mean birth weight (SD); minimum-maximum, g	3481 (418); 2570–4200
Symptoms at admission:	
Fever (>38°C), n (%)	14 (100)
Anxiety/irritability, n (%)	14 (100)
Abdominal symptoms, n (%)	8 (15.1)
Rash, n (%)	5 (35.7)
Duration of hospital stay, days	
Median (Q1; Q3); minimum-maximum	9 (8; 11); 5–14
Main etiological agent of infection	
Parechovirus, n (%)	11 (78.5)
Enterovirus, n (%)	3 (21.5)
Co-occurring pathogens	
Escherichia coli, n (%)	2 (14.2)
Candida parapsilosis, N (%)	1 (7.14)
Adenovirus, n (%)	1 (7.14)

Infected neonates were admitted to the ward because of fever (>38°C) and symptoms reported by parents such as anxiety, restlessness, and irritability, observed in all children. The symptoms lasted from few hours up to 1.5 day before admission. Poor feeding was reported by the parents of six neonates. Abdominal discomfort or pain were reported in eight cases, mucus in stool in three, one child had a single

episode of vomiting before the admission. None of the patients presented with cough or dyspnea. The family members (parents or siblings) of seven patients presented various symptoms of presumed infection (fever, cough, running nose, or diarrhea) in the days preceding the patients' admission. In physical examination on admission, five neonates had an unspecific rash: vesicles on the edges of feet in one child, micropapular rash on the chest or macular rash on the thorax in the remaining four (Table 1). Drying mouth mucosa or coated tongue were observed in 10 patients, in concordance with the fever. Abdominal flatulence, or sensitivity to palpation of abdominal cavity were reported in eight cases. Five had mottled skin, and two had prolonged (4–5 s) capillary refill. Reddened throat was observed in one neonate, two neonates had reddish tympanic membrane. Four patients were described as drowsy.

In four children presenting with symptoms of meningitis, a lumbar puncture was successfully performed on the first day of hospital stay, and viral RNA was detected in the cerebrospinal fluid using real time PCR: parechovirus was found in three children and enterovirus in one. In further five children, parechovirus RNA was isolated from cerebrospinal fluid collected later in the course of the disease. During the first two days of hospital stay, nasal swabs were collected from 10 children and examined for the presence of pneumotropic viruses: the RNA of parechovirus was detected in 8 (80%) while enterovirus in 2 (20%) patients.

Additionally, cultures of blood, urine and stool were conducted aiming at detecting any other infections, with an emphasis on bacteria. *Escherichia coli* (10^4 CFU/mL) was detected in urine samples of two children. *Candida parapsilosis* was cultivated from the stool of one infant and adenovirus DNA was detected in one nasal swab in addition to parechovirus RNA (Table 1). The results of the remaining microbiological tests were negative.

At admission, a panel of biochemical and hematologic tests was requested. The laboratory results were presented in Table 2. The most common laboratory sign was leukopenia in 50% of patients. In 5 children under 14 days old, erythrocyte counts were slightly reduced, in accordance with low hemoglobin. Inflammatory markers: C-reactive protein and procalcitonin were low. In nine neonates (64%), CRP was below the upper reference limit of 10 mg/L and in five patients (36%), slightly above the limit. Procalcitonin was within the reference range (<0.1 ng/mL) in all the patients. Biochemical tests including the activity of aspartate and alanine transaminases as well as urea, creatinine, glucose, sodium, potassium, magnesium, total calcium and chloride concentrations were within the reference ranges established for the appropriate age groups (Table 2).

Table 2. Results of hematological and biochemical laboratory tests among neonates with confirmed parechovirus or enterovirus infections.

Laboratory test (unit)	Results in the studied group		Age- and sex-specific reference intervals		
	Median (Q1–Q3) or mean \pm SD	Minimum–maximum	Age	Female	Male
Red blood cells ($\times 10^6/\mu\text{L}$)	3.6 (3.2–4.5)	2.9–5.9	0–14 days 14–30 days	4.12–5.74 3.32–4.8	4.10–5.55 3.16–4.63
Hemoglobin (g/dL)	12.6 (10.9–15.1)	9.9–20.6	0–14 days 14–30 days	13.4–20.0 10.8–14.6	13.9–19.1 10.0–15.3
Hematocrit (%)	34.8 (29.9–41.8)	27.2–58.7	0–14 days 14–30 days	39.6–57.2 32.0–44.5	39.8–53.6 30.3–45.0
MCV (fL)	93.5 \pm 2.93	89.2–99.2	0–14 days 14–30 days	92.7–106.4 90.1–103.0	91.3–103.1 89.4–99.7
MCH (pg)	33.3 (33.1–33.7)	32.4–36.2	0–14 days 14–30 days	31.1–35.9 30.4–35.3	31.3–35.6 29.9–34.1
MCHC (g/dL)	35.9 \pm 0.74	34.6–37.5	0–14 days 14–30 days	33.4–35.4 33.2–35.0	33.0–35.7 32.7–35.1
RDW-CV (%)	14 (14–15)	14–17	0–14 days 14–30 days	14.6–17.3 14.4–16.2	14.8–17.01 14.3–16.8
White blood cells ($\times 10^3/\mu\text{L}$)	6.0 (4.1–7.5)	3.04–14.16	0–14 days 14–30 days	8.16–14.56 8.36–14.42	
Neutrophils (%)	43 \pm 19.7	13.3–81	0–14 days 14–30 days	15.2–66.1 10.6–57.3	20.2–46.2 14.0–54.6
Lymphocytes (%)	36.4 \pm 15.1	8.2–56.6	0–14 days 14–30 days	24.9–68.5 31.9–82.7	33.7–67.6 33.6–76.8
Monocytes (%)	15.2 (13.6–25.1)	8.6–28.3	0–14 days 14–30 days	5.2–20.6 5.6–13.8	6.7–19.9 4.3–18.3
Eosinophils (%)	2.43 \pm 1.73	0.0–5.7	0–14 days 14–30 days	0.4–4.6 0.0–5.3	0.3–5.2 0.2–5.4
Basophils (%)	0.35 (0.3–0.7)	0.1–0.8	0–14 days 14–30 days	0.1–0.6 0.0–0.5	0.1–0.8 0.0–0.6
Immature granulocytes (%)	0.5 (0.4–0.7)	0.3–1.3	all age groups	<2	
Platelets ($\times 10^3/\mu\text{L}$)	292 \pm 97.9	148–475	0–14 days 14–30 days	144–449 279–571	218–419 248–586
C-reactive protein (mg/L)	5.5 (5–11)	5–14	all age groups	<10	

Table 2. Cont.

Laboratory test (unit)	Results in the studied group		Age- and sex-specific reference intervals		
	Median (Q1–Q3) or mean \pm SD	Minimum-maximum	Age	Female	Male
Procalcitonin (ng/mL)	0.17 (0.12–0.29)	0.07–0.4	all age groups	<0.5	
ALT (U/L)	36.6 \pm 8.9	19–52	1–7 days 7–30 days	18–39 18–44	23–38 20–45
AST (U/L)	41 (37–58)	27–79	1–7 days 7–30 days	24–95 24–72	30–100 20–70
Urea (mmol/L)	3.55 \pm 0.97	2.2–5.6	1–7 days 7–30 days	0.7–4.6 0.7–5.4	
Creatinine (μ mol/L)	31.7 \pm 4.42	25.9–40.4	1–7 days 7–30 days	53–97 27–62	
Glucose (mmol/L)	4.35 (4.18–4.89)	3.8–7.9	all age groups	3.33–5.55	
Potassium (mmol/L)	5.02 \pm 0.42	4.2–5.7	1–7 days 7–30 days	3.25–5.5 3.4–6.0	
Sodium (mmol/L)	137.2 \pm 3.1	130–141	all age groups	137–145	
Total calcium (mmol/L)	2.45 \pm 0.08	2.32–2.59	1–7 days 7–30 days	1.88–2.83 2.10–2.98	1.83–2.85 2.15–2.93
Magnesium (mmol/L)	2.45 \pm 0.08	2.32–2.59	1–7 days 7–30 days	0.48–1.05 0.65–1.0	
Chloride (mmol/L)	103.5 \pm 3.36	97–108	0–6 months	96–110	

Abbreviations: Q1 – lower quartile; Q3 – upper quartile; SD – standard deviation; MCV – mean cell volume; MCH – mean cell hemoglobin mass; MCHC – mean cell hemoglobin concentration; RDW-CV – red blood cells distribution width – coefficient of variation; ALT – alanine aminotransferase; AST – aspartate aminotransferase.

In nine children who underwent lumbar puncture, protein concentrations in the cerebrospinal fluid ranged from 50 to 89 mg/dL (upper reference limit 115 mg/dL). Low glucose concentrations (2.01 mmol/L) were found in three neonates: 2.01 mmol/L, 2.12 mmol/L, 2.19 mmol/L (lower reference limit: 2.00 mmol/L) and increased cell counts ($0.062\text{--}0.188 \times 10^3/\mu\text{L}$) in seven of the patients (upper reference limit: $0.026 \times 10^3/\mu\text{L}$). The percentage of polymorphonuclear cells in the cerebrospinal fluid ranged from 8.1% to 30.3%.

In 12 patients, meningitis of viral etiology was recognized as the final diagnosis: it was parechovirus infection in 10 neonates (83%) and enterovirus in two (17%). This group included the nine neonates with the viral RNA isolated from cerebrospinal

fluid samples and the other three, who developed the symptoms of meningitis during the hospital stay but had contraindications for lumbar puncture and the viral RNA was detected in nasal swab samples. In the remaining two patients, the diagnosis “other viral infections” (one parecho- and one enterovirus) was established according to International Classification of Diseases (ICD 9).

Discussion

Recently, human parechovirus and enterovirus infections have been the topic of increasing number of studies, however, in Poland the access to specialized virusological tests is still limited to bigger reference centers. The growing numbers of cases with high fever of unidentified etiology among children is a serious diagnostic problem [6–8]. Implementation of molecular methods could significantly contribute to a more specific diagnosis and a more effective treatment.

We retrospectively identified and summarized all cases of confirmed parecho- or enterovirus infections recorded in the neonates admitted to St. Louis Regional Children’s Hospital in Kraków, Poland since the introduction of diagnostic tests based on real time PCR method. In 2018, the largest number of cases was reported in June (6 cases) and July (3 cases), what confirms the observations of increased morbidity in the summer season [1, 9]. According to previous studies [4, 8, 10], neonates are the group most vulnerable to the infections; this susceptibility has been assigned to the immaturity of neonatal immunological system. In our study, all children presented symptoms of fever and irritability at admission, similar symptoms of parecho- and enterovirus infections have been observed by others [1, 8, 11]. Despite increased body temperature, inflammatory markers (CRP, PCT) remained unchanged in the majority of cases (only slight increase in serum CRP concentrations was observed in a few patients). This observation is similar to reported by Cabrerizo *et al.* [12]. This has also been observed by Chang *et al.* [1] and could be assigned to the immaturity of liver function, and thus limited production and secretion of acute phase proteins. Meningitis was diagnosed in most identified cases (85%), similarly to the reports of Britton *et al.* [13] and de Jong *et al.* [14].

There are, however, some discrepancies between the signs of infection observed in our patients and the ones reported previously. The rash occurred in less than 40% of neonates treated in our center, and its characteristics differed between these cases. Thus, we cannot regard the rash as a reliable symptom of parechovirus nor enterovirus infection. Cumming *et al.* [11] reported a rash in as much as 62% of children under three months of age, a significantly higher percentage than in our group. In another report, Sharp *et al.* [6] observed rash in seven out of 19 children [15]. Another symptom noted in Cumming *et al.* [11] is diarrhea, which developed in 31% of patients, however, it was not observed in our patients. In our group, the peripheral

blood cell counts revealed normal erythrocyte counts, hemoglobin concentrations and hematocrit as well as thrombocyte counts. Notably, a half of our patients had leukopenia, unlike the reports of other authors, who observed normal leukocyte counts [1, 16, 17]. Yeom *et al.* [18] described two cases with increased activity of aspartate aminotransferase, which also does not agree with our observations [18]. The diverse manifestations of the disease may be the result of the infections with different parechovirus and enterovirus genotypes.

Blood, urine and stool cultures were performed in our patients as a part of the diagnostic workup (search for etiological factor of high fever in neonates). All blood cultures remained sterile during the 5 days of incubation in aerobic environment. From two urine cultures, *Escherichia coli* was isolated in a titer of 10^4 CFU/mL. However, titers of at least 10^5 CFU/mL in urine collected by spontaneous urination in neonates or infants are considered diagnostic of urinary tract infections. Thus, the presence of *Escherichia coli* in urine samples was most likely the consequence of specimen contamination during collection. In turn, *Candida parapsilosis* cultured in stool samples colonizes the digestive tract of neonates.

Conclusions

In the reported parechovirus and enterovirus infections, non-specific symptoms such as fever, irritability and restlessness were observed and except for leukopenia no significant abnormalities were noted in basic laboratory tests. The identification of the etiological factor of the disease was possible due to implementation of molecular method, i.e. real time PCR. In the light of more widespread availability of molecular techniques in medical diagnostics, identification of extended panel of viruses should be considered in children presenting with fever of unknown etiology. The sensitivity of molecular methods opens a possibility to detect scant genetic material of a pathogen even in a modest amount of specimen. This is especially valid in neonates and premature infants when only small volumes of biological samples (in particular blood and cerebrospinal fluid) may be acquired for laboratory tests.

Conflict of interest

None declared.

References

1. Chang J.T., Chen Y.S., Chen B.C., Huang T.S., Chang T.H.: Human Parechovirus Infection in Children in Taiwan: a Retrospective, Single-Hospital Study. *Jpn J Infect Dis.* 2018; 7: 291–297.
2. Watanabe K., Oie M., Higuchi M., Nishikawa M., Fujii M.: Isolation and characterization of novel human parechovirus from clinical samples. *Emerg Infect Dis.* 2007; 13: 889–895.

3. Tang J.W., Holmes C.H., Elsanousi F.A., Patel A., Adam F., Speight R., et al.: Cluster of human parechovirus infections as the predominant cause of sepsis in neonates and infants, Leicester, United Kingdom, 8 May to 2 August 2016. *Euro Surveill.* 2016; 21: 30326.
4. Volpe J.J.: Neonatal encephalitis and white matter injury: more than just inflammation? *Ann Neurol.* 2008; 64: 232–236.
5. de Crom S.C., Rossen J.W., van Furth A.M., Obihara C.C.: Enterovirus and parechovirus infection in children: a brief overview. *Eur J Pediatr.* 2016; 175: 1023–1029.
6. Sharp J., Bell J., Harrison C.J., Nix W.A., Oberste M.S., Selvarangan R.: Human parechovirus in respiratory specimens from children in Kansas City, Missouri. *J Clin Microbiol.* 2012; 50: 4111–4113.
7. Strenger V., Diedrich S., Boettcher S., Richter S., Maritschnegg P., Gangl D., et al.: Nosocomial Outbreak of Parechovirus 3 Infection among Newborns, Austria, 2014. *Emerg Infect Dis.* 2016; 22: 1631–1634.
8. Sharp J., Harrison C.J., Puckett K., Selvaraju S.B., Penaranda S., Nix W.A., et al.: Characteristics of young infants in whom human parechovirus, enterovirus or neither were detected in cerebrospinal fluid during sepsis evaluations. *Pediatr Infect Dis J.* 2013; 32: 213–216.
9. Colvin J.M., Muenzer J.T., Jaffe D.M., Smason A., Deych E., Shannon W.D., et al.: Detection of viruses in young children with fever without an apparent source. *Pediatrics.* 2012; 130: e1455–1462.
10. Boivin G., Abed Y., Boucher F.D.: Human parechovirus 3 and neonatal infections. *Emerg Infect Dis.* 2005; 11: 103–105.
11. Cumming G., Khatami A., McMullan B.J., Musto J., Leung K., Nguyen O., et al.: Parechovirus Genotype 3 Outbreak among Infants, New South Wales, Australia, 2013–2014. *Emerg Infect Dis.* 2015; 21: 1144–1152.
12. Cabrerizo M., Trallero G., Pena M.J., Cilla A., Megias G., Muñoz-Almagro C., et al.: Comparison of epidemiology and clinical characteristics of infections by human parechovirus vs. those by enterovirus during the first month of life. *Eur J Pediatr.* 2015; 174: 1511–1516.
13. Britton P.N., Dale R.C., Nissen M.D., Crawford N., Elliott E., Macartney K., et al.: Parechovirus encephalitis and neurodevelopmental outcomes. *Pediatrics.* 2016; 137: e20152848.
14. de Jong E.P., Holscher H.C., Steggerda S.J., Van Klink J.M.M., van Elzakker E.P.M., Lopriore E., et al.: Cerebral imaging and neurodevelopmental outcome after entero- and human parechovirus sepsis in young infants. *Eur J Pediatr.* 2017; 176: 1595–1602.
15. Sharp J., Harrison C.J., Puckett K., Selvaraju S.B., Penaranda S., Nix W.A., et al.: Characteristics of young infants in whom human parechovirus, enterovirus or neither were detected in cerebrospinal fluid during sepsis evaluations. *Pediatr Infect Dis J.* 2013; 32: 213–216.
16. van der Sanden S., de Bruin E., Vennema H., Swanink C., Koopmans M., van der Avoort H.: Prevalence of human parechovirus in the Netherlands in 2000 to 2007. *J Clin Microbiol.* 2008; 46: 2884–2889.
17. Nelson T.M., Vuillermin P., Hodge J., Druce J., Williams D.T., Jasrotia R., et al.: An outbreak of severe infections among Australian infants caused by a novel recombinant strain of human parechovirus type 3. *Sci Rep.* 2017; 7: 44423.
18. Yeom J.S., Park J.S., Seo J.H., Park E.S., Lim J.Y., Park C.H., et al.: Distinctive clinical features of HPeV-3 infection in 2 neonates with a sepsis-like illness. *Korean J Pediatr.* 2016; 59: 308–311.